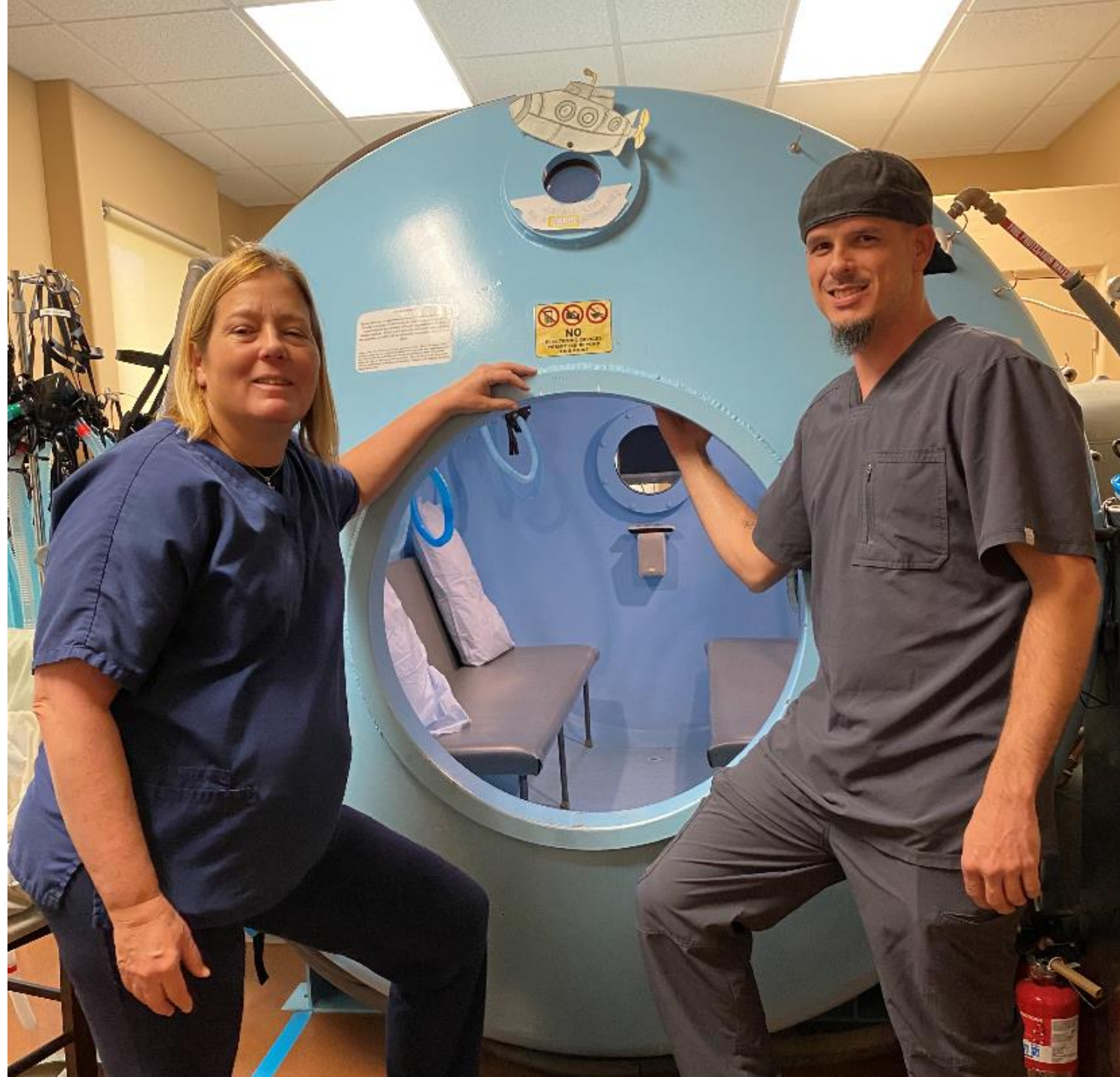

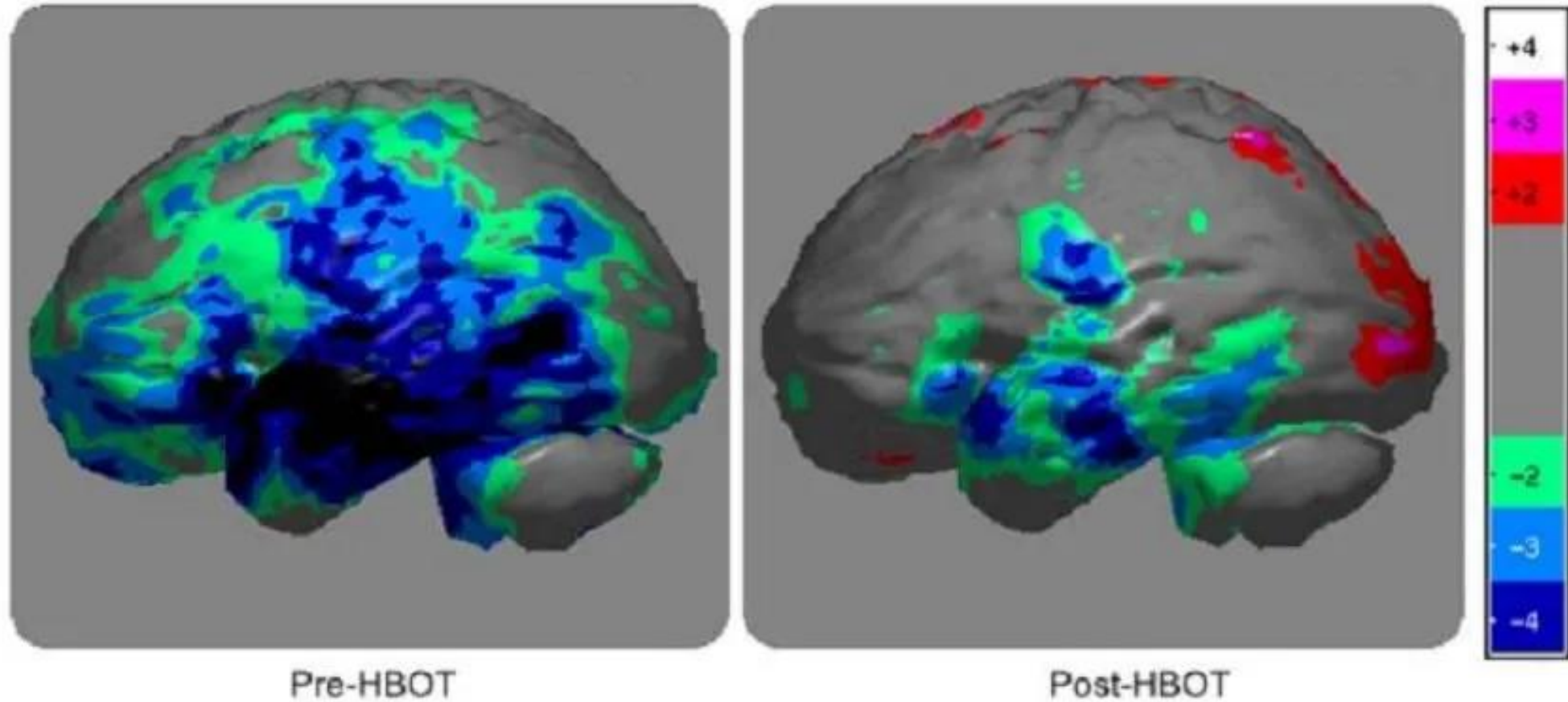
HR 119  
Hyperbaric Oxygen  
Therapy for Veterans

House Military, Veterans, and Homeland  
Security Committee

June 13, 2023

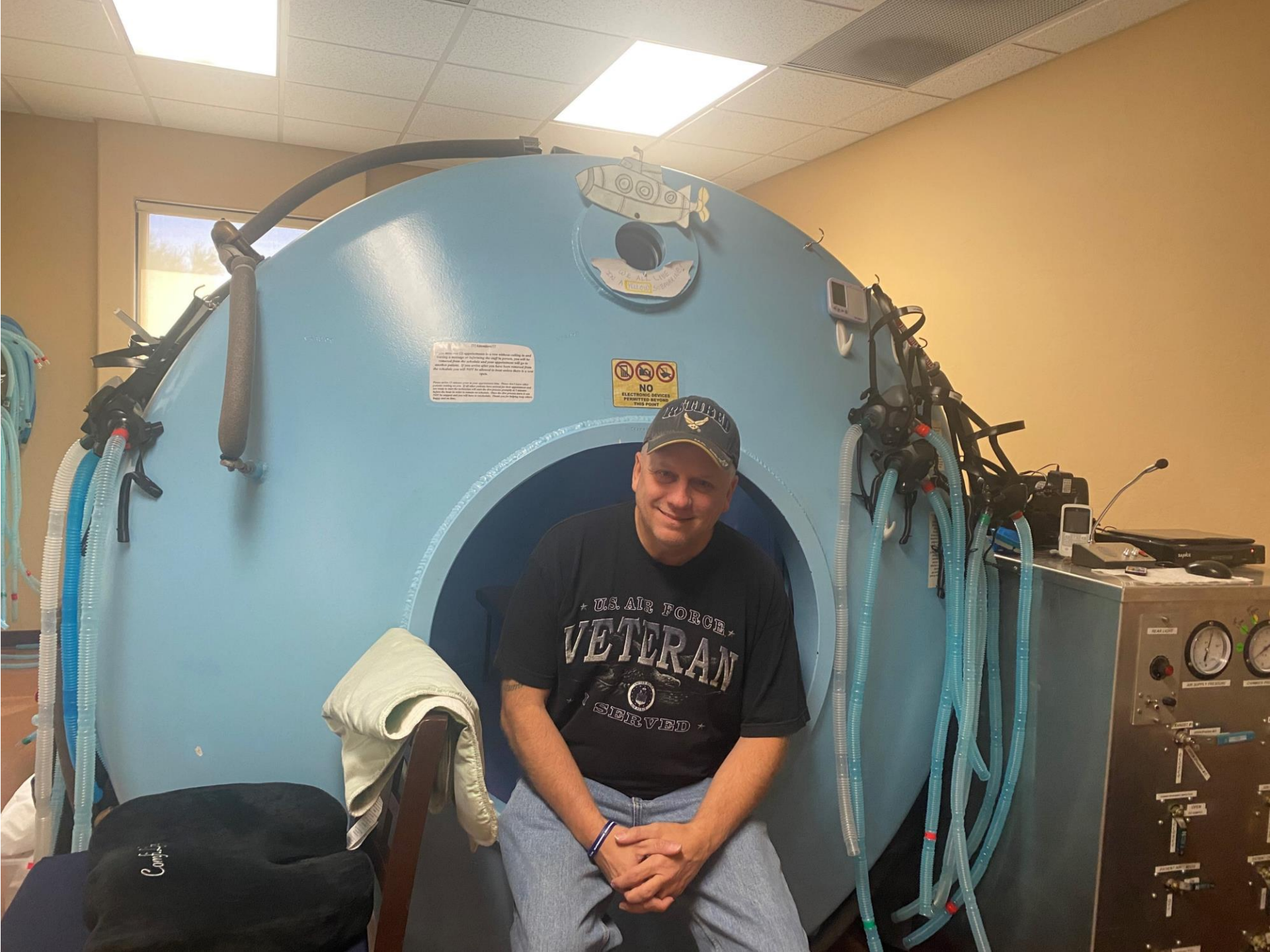

Brain SPECT Scan Image with Colorimetric Scale: Grey—normal blood flow/ perfusion. Light Green—slightly reduced perfusion. Light blue—moderately reduced perfusion. Dark blue/black—severely reduced perfusion.



The Veteran's brain SPECT scan illustrates the changes in color in the temporal lobe of the brain after HBOT from dark blue to light blue and green colors.



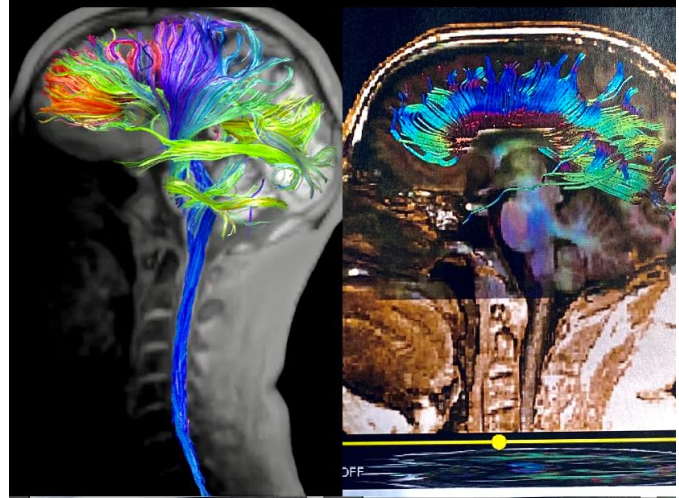
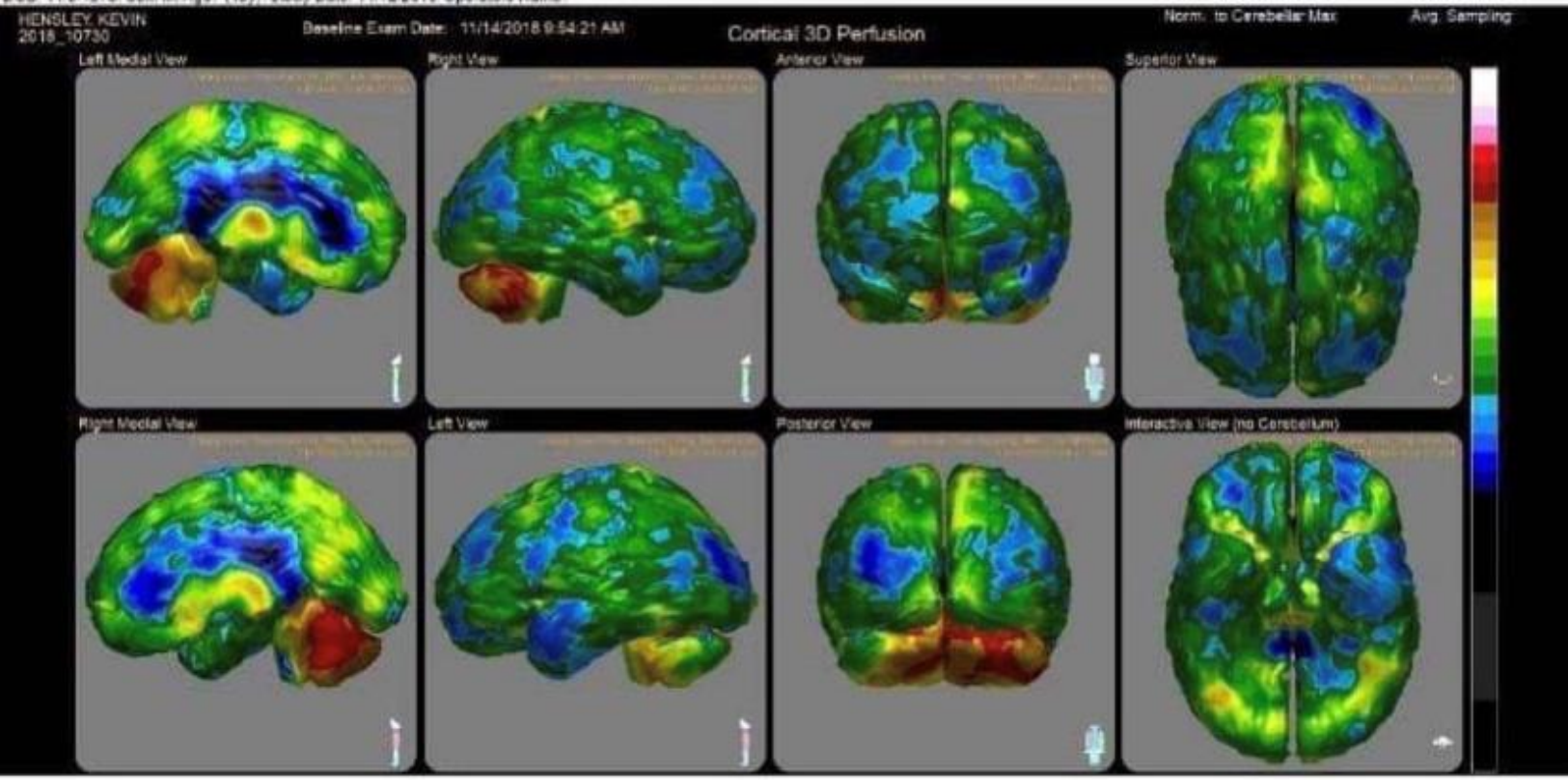


Caution: This chamber is a pressurized vessel and should be operated only by trained personnel. If you are not a trained operator, do not enter the chamber. If you are a trained operator, do not enter the chamber unless you are properly trained and authorized to do so. For more information, see the operator's manual.

**NO ELECTRONIC DEVICES PERMITTED BEYOND THIS POINT**

Complete





# Veteran's With Constrictive Bronchiolitis

Sep 20, 2020 · 🌐